

Teacher Packet for Skeletal System

Overview of Anatomy and Physiology “Crash Course” Questions Answers

(2 pts/piece 30 In Class Points on 1st grad in 2nd quarter)

Objective: Review material from unit #1-3 and preview unit #5 on the skeletal system

Introduction to Anatomy and Physiology (11 minutes)

https://www.youtube.com/watch?v=uBGI2BujkPQ&list=PL8dPuuaLjXtOAKed_MxxWBNaPno5h3Zs8

1. Why did Britain pass the Anatomy Act? Provide bodies from murders for students to dissect
2. What has dissecting bodies shown us? That function follows form
3. The basic idea to what a structure can do depends upon? The complementarity of structure and function
4. Fill in the correct words here: chemical, cellular, tissue, _____, _____, the body. Organ, organ system
5. The ability to maintain stable, internal conditionings no matter what changes are occurring outside the body is: _____ homoeostasis

The skeletal system #19 (11 minutes)

https://youtu.be/rDGqkMHPDqE?list=PL8dPuuaLjXtOAKed_MxxWBNaPno5h3Zs8

6. Perhaps the most serious damage a microgravity environment causes is to the _____. bones
7. Bones are made of what type of tissue? _____ (connective)
8. Blood cell production is called _____ hematopoiesis
9. How many bones in the body? _____ 206
10. The _____ bones are found near the center of the body (skull, vertebral column, and thoracic) while the _____ bones are everything else toward the outside of the body. Axial, appendicular
11. There are different _____ of bones. shapes
12. The basic structure of bones is called _____ osteons
13. Mature bone cells that maintain and monitor your bone matrix _____ osteocytes

14. There two main work horses in bone including the _____ (bone makers) and the _____ (bone breaker downers). Osteoblasts, osteoclasts
15. The process of fixing up your bones is called _____ (remodeling)

Joint Movement Lab Answers

Name _____

Date _____

Directions: You will be asked to move certain parts of your body, determine the type of movement and/or joint involved. Be as specific as possible.

1. Move your jaw outward (anterior).
 - a. Name of the movement/name of the bone moved- _____ / _____ (hinge/mandible)
2. While sitting on a chair or stool, turn your feet inward so that the soles face each other.
 - a. Name of the movement (anatomically)/name of the bones/group moved- _____ / _____ (adduction/ankle)
3. Move your arms laterally and upward until it reaches the horizontal position to the ground.
 - a. Name this movement/joint at which movement occurred- _____ / _____ (frontal raise/shoulder)
4. Bend your arm at center so your hand touches your shoulder
 - a. Name this movement/joint at which movement occurred. _____ / _____ (hinge/elbow)
5. Rotate your forearm so your palm faces backward (posteriorly).
 - a. Name this movement/joint/s at which movement occurred. _____ / _____ (supination/wrist)
6. Turn your head from side to side as if you are saying "no"
 - a. Name this movement/joint at which movement occurred. _____ / _____ (transverse/cervical vertebra)
7. While standing move your thigh forward, raising the entire leg off the floor.
 - a. Name this movement of the thigh/joint where occurred. _____ / _____ (sagittal/hip)
8. Open your mouth wide.

- a. Name this movement/joint at which movement occurred.
_____/_____ (frontal/mandible)
9. Raise your shoulders in a shrugging motion.
- a. Name this movement/name two main bones involved.
_____/_____ (frontal/clavicle/arm)
10. Straighten your upper limbs to the sky to it forms a cone in the air.
- a. Name this movement/joint involved. _____/_____
(frontal & sagittal/shoulder)
11. While sitting, raise one leg to the horizontal position. Then bend your foot at the ankle so that your toes point to the same object.
- a. Name of latter movement/joint involved. _____/_____
(sagittal/hip & ankle)
12. Twist your forearm right & left.
- a. Describe how you made this movement/joint involved.
_____/_____ (turn & transverse/elbow & wrist)
13. While standing flex your thigh backward (static/stationary)
- a. Describe how you made this movement/joint involved.
_____/_____ (sagittal/hip)
14. Extend your lumbar region.
- a. Describe how you made this movement/joint involved.
_____/_____ (sagittal/lower lumbar)
15. Flex your head (downward).
- a. How did you do this movement-_____ (skull downward using cervical vertebra)
16. Rotate your trunk right and left.
- a. How did you do this movement-_____ (transverse whole upper extremity)
17. Standing flat footed and extend your body upward on your tip toes
- a. Name of movement/joints involved. _____/_____
(frontal, ankle extension)

CGHS 16-17 6th Period (APMORLAND201617)

[My Courses](#) | [Course Settings](#)

Essentials of Human Anatomy and Physiology, 11e
Marieb

[Instructor Resources](#) [eText](#) [Study Area \(myA&P\)](#)

[Course Home](#)

[Assignments](#)

[Roster](#)

[Gradebook](#)

[Item Library](#)

Chapter 5 Skeletal System Homework [\[Edit \]](#)

[Overview](#) [Summary View](#) [Diagnostics View](#) **[Print View with Answers](#)**

Chapter 5 Skeletal System Homework

Due: 11:00pm on Thursday, October 27, 2016

To understand how points are awarded, read the [Grading Policy](#) for this assignment.

Art Labeling Activity: Figure 5.3 (1 of 2)

Description: The structure of a long bone (humerus of arm)—anterior view.

Part A

Drag the appropriate labels to their respective targets.

ANSWER:

Chapter 5 Chapter Test Question 3

Description: [[Bloom's Taxonomy: Remembering]] (a) What term refers to the end of a long bone?

Part A

What term refers to the end of a long bone?

ANSWER:

- ☐ *diaphysis*
- ☒ *epiphysis*
- ☐ *medullary cavity*
- ☐ *epiphyseal line*

Chapter 5 Reading Quiz Question 1

Description: [[Bloom's Taxonomy: Remembering]] (a) What is the function of red bone marrow?

Part A

What is the function of red bone marrow?

ANSWER:

- ☒ blood cell formation
- ☐ fat storage
- ☐ mineral storage
- ☐ glucose storage

Chapter 5 Reading Quiz Question 2

Description: [[Bloom's Taxonomy: Applying]] (a) Which of these allow nutrients to diffuse from the central canal to all the osteocytes within an osteon?

Part A

Which of these allow nutrients to diffuse from the central canal to all the osteocytes within an osteon?

ANSWER:

- ☐ lacunae
- ☒ canaliculi
- ☐ lamellae
- ☐ perforating canals

Chapter 5 Chapter Test Question 13

Description: [[Bloom's Taxonomy: Remembering]] (a) Which bones form the shoulder joint?

Part A

Which bones form the shoulder joint?

ANSWER:

- ☐ scapula, clavicle, and humerus
- ☐ scapula and clavicle
- ☐ clavicle and humerus
- ☒ scapula and humerus

Interactive Activity: Bones of the Upper and Lower Limbs


Description: [[Bloom's Taxonomy: Comprehension]] These six labeling activities on shoulder and pelvic girdles assess identification of the girdle bones and their attached limb bones.

Part A - Labeling Shoulder Girdle and Upper Limb

Identify the bones of the shoulder and upper limb.

Drag and drop the terms on the left to their correct location in the illustration of the shoulder girdle and upper limb on the right.

ANSWER:



Part B - Labeling Wrist and Hand

Identify the bones of the right wrist and hand, anterior view.

Drag and drop the terms on the left to their correct location in the illustration of the wrist and hand on the right.

ANSWER:

A large, empty rectangular box with a thin black border, intended for the user to provide their answer to the labeling task.

Part C - Labeling Wrist Bones

Identify the bones of the wrist.

Drag and drop the terms on the left to their correct location in the illustration of the wrist on the right.

ANSWER:




Part D - Labeling Pelvic Girdle and Lower Limb

Identify the bones of the pelvic girdle and lower limb.

Drag and drop the terms on the left to their correct location in the illustration of the pelvic girdle and lower limb on the right.

ANSWER:



Part E - Labeling Pelvic Girdle

Identify the bones of the pelvic girdle: the articulated pelvis above, and the right coxal (hip) bone below.

Drag and drop the terms on the left to their correct location in the illustration of the pelvic girdle on the right. Labels can be used more than once.

ANSWER:

Part F - Labeling Ankle and Foot Bones

Identify the bones of the right ankle and foot, superior view.

Drag and drop the terms on the left to their correct location in the illustration of the ankle and foot on the right.

ANSWER:



Chapter 5 Chapter Test Question 11

Description: [[Bloom's Taxonomy: Understanding]] (a) What is the region of the coxal bone that bears most of the body weight when a person is sitting?

Part A

What is the region of the coxal bone that bears most of the body weight when a person is sitting?

ANSWER:

- ☒ ischial tuberosity
- ☐ pubis
- ☐ greater sciatic notch
- ☐ iliac crest

Chapter 5 Chapter Test Question 14

Description: [[Bloom's Taxonomy: Remembering]] (a) How is a ball-and-socket joint classified?

Part A

How is a ball-and-socket joint classified?

ANSWER:

- ☐ fibrous joint
- ☐ amphiarthrosis
- ☒ synovial joint
- ☐ cartilaginous joint

Art Labeling Activity: Figure 5.3 (2 of 2)

Description: The structure of a long bone (humerus of arm)—enlarged cross-sectional view of the shaft.

Part A

Drag the appropriate labels to their respective targets.

ANSWER:

Art Labeling Activity: Figure 5.2

Description: Classification of bones on the basis of shape.

Part A

Drag the appropriate labels to their respective targets.

ANSWER:

Chapter 5 Chapter Test Question 1

Description: [[Bloom's Taxonomy: Understanding]] (a) Which of these is a function of the skeletal system?

Part A

Which of these is a function of the skeletal system?

ANSWER:

- ☐ communication system
- ☐ creation of the structural framework within soft organs of the body
- ☒ storage site for calcium
- ☐ removal of old or damaged blood cells

Chapter 5 Chapter Test Question 5

Description: [[Bloom's Taxonomy: Applying]] (a) Which of these is responsible for the flexibility of bone?

Part A

Which of these is responsible for the flexibility of bone?

ANSWER:

- ☐ canaliculi
- ☐ calcium salts
- ☒ collagen
- ☐ cartilage

Chapter 5 Chapter Test Question 7

Description: [[Bloom's Taxonomy: Applying]] (a) Which of these bones is most susceptible to fractures?

Part A

Which of these bones is most susceptible to fractures?

ANSWER:

- ☐ phalanges
- ☐ ribs
- ☒ osteoporotic bones
- ☐ wrist bones in toddlers

Chapter 5 Matching Question 6-10

Description: [[Bloom's Taxonomy: Knowledge]] (a) Match the following.

Part A

Match the following.

Drag the terms on the left to the appropriate blanks on the right.

ANSWER:

Reset **Help**

1. **Osteoclasts** Cells that can dissolve the bony matrix
2. **Lamellae** Layers or rings of calcification that are found in compact bone
3. **Canaliculi** Small channels that radiate through the matrix of compact bone
4. **Osteoblasts** Cells that can build bony matrix
5. **Epiphyseal plate** Area where bone growth takes place in a long bone

Chapter 5 Matching Question 16-25

Description: [[Bloom's Taxonomy: Knowledge]] (a) Match the following.

Part A

Match the following.

Drag the terms on the left to the appropriate blanks on the right.

ANSWER:

Reset

Help

appendicular skeleton

axial skeleton

1. **Axial skeleton** True ribs.
2. **Axial skeleton** Atlas.
3. **Appendicular skeleton** Ulna.
4. **Axial skeleton** Sternum.
5. **Appendicular skeleton** Tarsals.
6. **Appendicular skeleton** Coxal bone.
7. **Appendicular skeleton** Phalanges.
8. **Axial skeleton** Parietal bones.
9. **Appendicular skeleton** Femur.
10. **Appendicular skeleton** Fibula.

Chapter 5 Multiple Choice, Part I, Question 1

Description: [[Bloom's Taxonomy: Knowledge]] (a) Using the figure, identify the following: The proximal epiphysis is represented by _____.

Part A

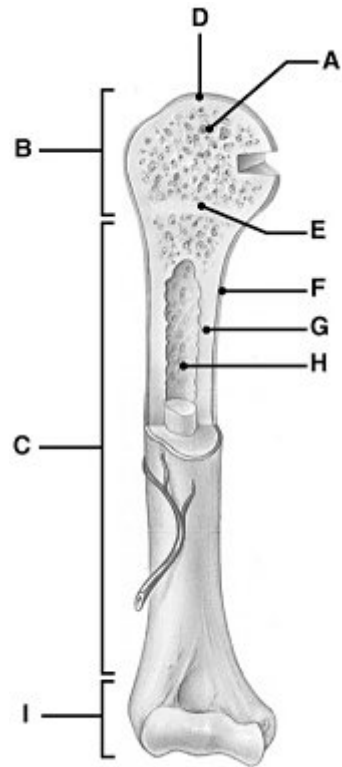


Figure 5.1

Using the figure, identify the following:

The proximal epiphysis is represented by _____.

ANSWER:

- ☐ Label H
- ☐ Label C
- ☐ Label A
- ☒ Label B
- ☐ Label F

Chapter 5 Multiple Choice, Part I, Question 2

Description: [[Bloom's Taxonomy: Comprehension]] (a) Using the figure, identify the following: The area that causes the lengthwise growth of a long bone is indicated by _____.

Part A

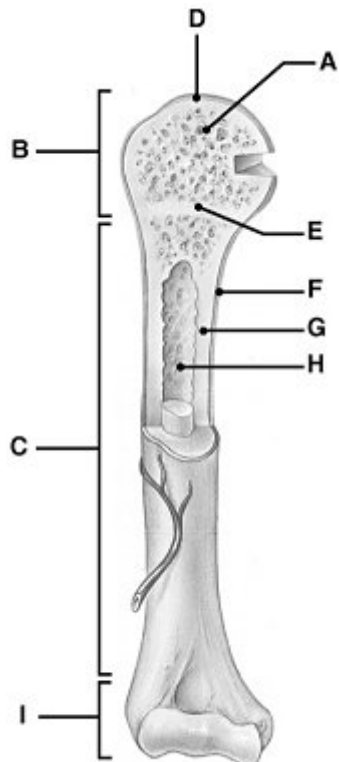


Figure 5.1

Using the figure, identify the following:

The area that causes the lengthwise growth of a long bone is indicated by _____.

ANSWER:

- ☐ Label F
- ☐ Label D
- ☐ Label A
- ☒ Label E
- ☐ Label C

Chapter 5 Multiple Choice, Part I, Question 3

Description: [[Bloom's Taxonomy: Comprehension]] (a) Using the figure, identify the following: The area that serves as a storage area for fat in adults is indicated by _____.

Part A

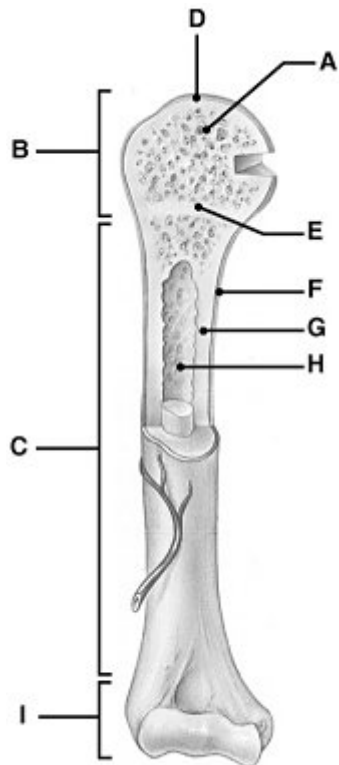


Figure 5.1

Using the figure, identify the following:

The area that serves as a storage area for fat in adults is indicated by _____.

ANSWER:

- ☒ Label H
- ☐ Label F
- ☐ Label A
- ☐ Label G
- ☐ Label B

Description: [[Bloom's Taxonomy: Knowledge]] (a) Using the figure, identify the following: The diaphysis is indicated by _____.

Part A

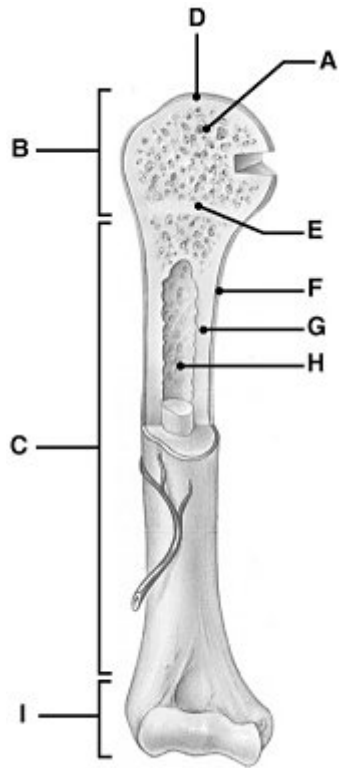


Figure 5.1

Using the figure, identify the following:

The diaphysis is indicated by _____.

ANSWER:

- ☐ Label D
- ☒ Label C
- ☐ Label G
- ☐ Label A
- ☐ Label H

Chapter 5 Multiple Choice, Part I, Question 5

Description: [[Bloom's Taxonomy: Comprehension]] (a) Using the figure, identify the following: The periosteum, a connective tissue covering on the diaphysis, is represented by _____.

Part A

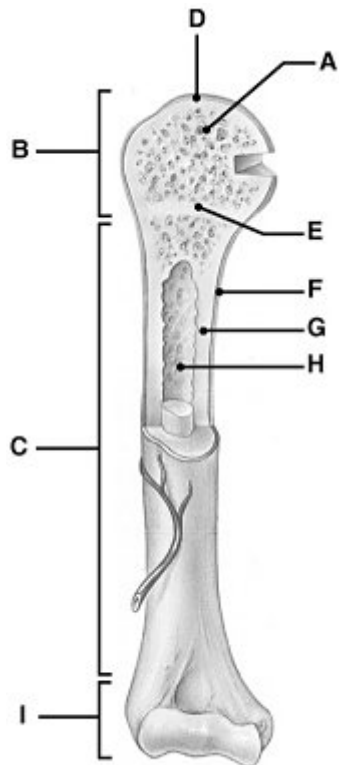


Figure 5.1

Using the figure, identify the following:

The periosteum, a connective tissue covering on the diaphysis, is represented by _____.

ANSWER:

- ☐ Label C
- ☐ Label A
- ☐ Label G
- ☐ Label B
- ☒ Label F

Description: [[Bloom's Taxonomy: Comprehension]] (a) Using the figure, identify the following: The area that contains glassy hyaline cartilage that provides a smooth slippery surface which decreases friction is indicated by _____.

Part A

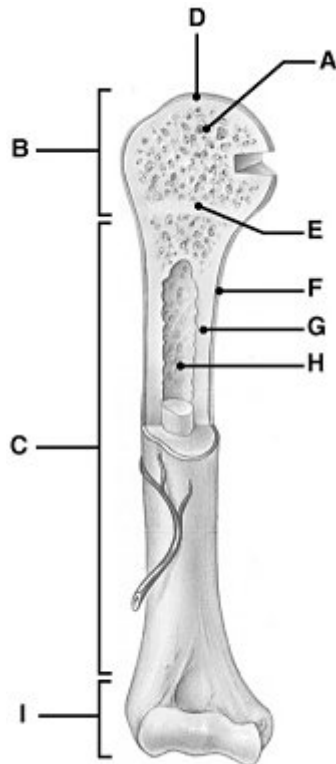


Figure 5.1

Using the figure, identify the following:

The area that contains glassy hyaline cartilage that provides a smooth slippery surface which decreases friction is indicated by _____.

ANSWER:

- ☒ Label D
- ☐ Label H
- ☐ Label E
- ☐ Label B
- ☐ Label A

Chapter 5 Multiple Choice, Part I, Question 7

Description: [[Bloom's Taxonomy: Knowledge]] (a) Blood cell formation is called _____.

Part A

Blood cell formation is called _____.

ANSWER:

- ☒ hematopoiesis
- ☐ ossification
- ☐ metabolism
- ☐ homeostasis

Chapter 5 Multiple Choice, Part I, Question 8

Description: [[Bloom's Taxonomy: Knowledge]] (a) What bones protect the spinal cord?

Part A

What bones protect the spinal cord?

ANSWER:

- ☐ sternum
- ☐ ribs
- ☒ vertebrae
- ☐ coxal bones

Chapter 5 Multiple Choice, Part I, Question 9

Description: [[Bloom's Taxonomy: Knowledge]] (a) Cube-shaped bones that contain mostly spongy bone are called _____ bones.

Part A

Cube-shaped bones that contain mostly spongy bone are called _____ bones.

ANSWER:

- ☐ flat
- ☐ long
- ☒ short
- ☐ irregular

Chapter 5 Multiple Choice, Part I, Question 10

Description: [[Bloom's Taxonomy: Knowledge]] (a) Small canals that connect osteocytes in their lacunae to the central canal are known as _____.

Part A

Small canals that connect osteocytes in their lacunae to the central canal are known as _____.

ANSWER:

- ☒ canaliculi
- ☐ perforating (Sharpey's) fibers
- ☐ perforating (Volkmann's) canals
- ☐ central (Haversian) canals

Chapter 5 Multiple Choice, Part I, Question 11

Description: [[Bloom's Taxonomy: Knowledge]] (a) The process of bone formation is known as _____.

Part A

The process of bone formation is known as _____.

ANSWER:

- ☐ hemostasis
- ☐ metabolism
- ☒ ossification
- ☐ hematopoiesis

Chapter 5 Multiple Choice, Part I, Question 15

Description: [[Bloom's Taxonomy: Knowledge]] (a) The skull, vertebral column, and thoracic cage form the _____ skeleton.

Part A

The skull, vertebral column, and thoracic cage form the _____ skeleton.

ANSWER:

- ☐ central
- ☐ main
- ☐ appendicular
- ☒ axial

Chapter 5 Multiple Choice, Part II, Question 2

Description: [[Bloom's Taxonomy: Comprehension]] (a) The arrangement of bone tissue shown in the figure consists of _____.

Part A




Figure 5.3

The arrangement of bone tissue shown in the figure consists of _____.

ANSWER:

- ☐ yellow marrow
- ☒ osteons (Haversian systems)
- ☐ neurons
- ☐ trabeculae
- ☐ red marrow

Chapter 5 Multiple Choice, Part II, Question 3

Description: [[Bloom's Taxonomy: Comprehension]] (a) Where does hematopoiesis occur?

Part A

Where does hematopoiesis occur?

ANSWER:

- ☐ articular cartilage
- ☐ epiphyseal plate
- ☒ marrow cavity
- ☐ endosteum
- ☐ periosteum

Chapter 5 Multiple Choice, Part II, Question 4

Description: [[Bloom's Taxonomy: Comprehension]] (a) The femur, tibia, humerus, and radius are all classified as _____.

Part A

The femur, tibia, humerus, and radius are all classified as _____.

ANSWER:

- ☐ compact bones
- ☐ flat bones
- ☒ long bones
- ☐ irregular bones
- ☐ sesamoid bones

Chapter 5 Multiple Choice, Part II, Question 5

Description: [[Bloom's Taxonomy: Knowledge]] (a) What type of tissue covers the epiphysis of bones and reduces friction in the joints?

Part A

What type of tissue covers the epiphysis of bones and reduces friction in the joints?

ANSWER:

- ☐ periosteum
- ☐ spongy bone
- ☐ endosteum
- ☐ yellow marrow
- ☒ articular cartilage

Chapter 5 Multiple Choice, Part II, Question 6

Description: [[Bloom's Taxonomy: Comprehension]] (a) In adults, the function of the yellow marrow is to _____.

Part A

In adults, the function of the yellow marrow is to _____.

ANSWER:

- ☐ decrease friction at joint surfaces
- ☐ promote lengthwise growth in long bones
- ☐ store calcium and phosphorus
- ☒ store adipose tissue
- ☐ form blood cells

Chapter 5 Multiple Choice, Part II, Question 7

Description: [[Bloom's Taxonomy: Application]] (a) The presence of an epiphyseal plate indicates that _____.

Part A

The presence of an epiphyseal plate indicates that _____.

ANSWER:

- ☐ bone is dead
- ☐ bone length is no longer increasing
- ☐ bone diameter is increasing
- ☒ bone length is increasing
- ☐ bone diameter is decreasing

Chapter 5 Multiple Choice, Part II, Question 8

Description: [[Bloom's Taxonomy: Comprehension]] (a) Each complex of central canal and matrix rings in compact bone is known as _____.

Part A

Each complex of central canal and matrix rings in compact bone is known as _____.

ANSWER:

- ☐ a canaliculus
- ☒ an osteon (Haversian system)
- ☐ a perforating (Volkmann's) canal
- ☐ the epiphysis
- ☐ a central (Haversian) canal

Chapter 5 Multiple Choice, Part II, Question 9

Description: [[Bloom's Taxonomy: Comprehension]] (a) The bone cells that respond to parathyroid hormone (PTH) to destroy bone matrix and release calcium into the blood are called _____.

Part A

The bone cells that respond to parathyroid hormone (PTH) to destroy bone matrix and release calcium into the blood are called _____.

ANSWER:

- ☒ osteoclasts
- ☐ osteocytes
- ☐ erythrocytes
- ☐ chondrocytes
- ☐ osteoblasts

Chapter 5 Multiple Choice, Part II, Question 11

Description: [[Bloom's Taxonomy: Comprehension]] (a) Which of these bone markings is a projection that serves as a site for muscle or ligament attachment?

Part A

Which of these bone markings is a projection that serves as a site for muscle or ligament attachment?

ANSWER:

- ☐ meatus
- ☐ fissure
- ☐ foramen
- ☐ fossa
- ☒ tubercle

Chapter 5 Multiple Choice, Part II, Question 13

Description: [[Bloom's Taxonomy: Knowledge]] (a) The canal that runs through the core of each osteon (Haversian system) contains _____.

Part A

The canal that runs through the core of each osteon (Haversian system) contains _____.

ANSWER:

- ☐ yellow marrow and perforating, or Sharpey's, fibers
- ☐ red marrow
- ☒ blood vessels and nerve fibers
- ☐ cartilage and lamellae
- ☐ osteoclasts and osteoblasts

Chapter 5 Multiple Choice, Part II, Question 14

Description: [[Bloom's Taxonomy: Knowledge]] (a) The small cavities in bone tissue where osteocytes are found are called _____.

Part A

The small cavities in bone tissue where osteocytes are found are called _____.

ANSWER:

- ☐ perforating (Volkmann's) canals
- ☐ lamellae
- ☐ trabeculae
- ☒ lacunae
- ☐ central (Haversian) canals

Chapter 5 Multiple Choice, Part II, Question 15

Description: [[Bloom's Taxonomy: Knowledge]] (a) What kind of tissue is the forerunner of long bones in the embryo?

Part A

What kind of tissue is the forerunner of long bones in the embryo?

ANSWER:

- ☐ loose fibrous connective tissue
- ☐ fibrocartilage
- ☐ dense fibrous connective tissue
- ☐ elastic connective tissue
- ☒ hyaline cartilage

Chapter 5 Multiple Choice, Part II, Question 16

Description: [[Bloom's Taxonomy: Comprehension]] (a) What type of bone cell is primarily active when bone growth occurs?

Part A

What type of bone cell is primarily active when bone growth occurs?

ANSWER:

- ☐ chondrocyte
- ☒ osteoblast
- ☐ erythrocyte
- ☐ osteoclast
- ☐ osteocyte

Chapter 5 Multiple Choice, Part II, Question 20

Description: [[Bloom's Taxonomy: Comprehension]] (a) An open, or compound, fracture can be described as when _____.

Part A

An open, or compound, fracture can be described as when _____.

ANSWER:

- ☐ adjacent bones fracture simultaneously
- ☒ the broken bone is exposed to the outside
- ☐ the bone is crushed
- ☐ the broken bone ends are forced into each other
- ☐ the bone is broken into many fragments

Chapter 5 Multiple Choice, Part II, Question 21

Description: [[Bloom's Taxonomy: Comprehension]] (a) A bone fracture where the bone is broken into many fragments is a _____.

Part A

A bone fracture where the bone is broken into many fragments is a _____.

ANSWER:

- ☐ simple fracture
- ☐ compression fracture
- ☐ greenstick fracture
- ☐ compound fracture
- ☒ comminuted fracture

Chapter 5 Multiple Choice, Part II, Question 23

Description: [[Bloom's Taxonomy: Comprehension]] (a) A fracture that is common in osteoporotic bones is a(n) _____.

Part A

A fracture that is common in osteoporotic bones is a(n) _____.

ANSWER:

- ☐ simple fracture
- ☐ spiral fracture
- ☐ impacted fracture
- ☐ depressed fracture
- ☒ compression fracture

Chapter 5 Multiple Choice, Part II, Question 24

Description: [[Bloom's Taxonomy: Analysis]] (a) The axial skeleton contains _____. 1. skull 2. scapula 3. true and false ribs 4. vertebrae 5. phalanges...

Part A

The axial skeleton contains _____.

1. skull
2. scapula

- 3. true and false ribs
- 4. vertebrae
- 5. phalanges

ANSWER:

- ☐ 1, 3, 4, 5
- ☐ 2, 3, 4, 5
- ☐ 2, 5
- ☐ 1, 2, 3, 5
- ☒ 1, 3, 4

Chapter 5 True/False Question 1

Description: [[Bloom's Taxonomy: Comprehension]] (a) Hematopoiesis refers to the formation of blood cells within the red marrow cavities of certain bones.

Part A

Hematopoiesis refers to the formation of blood cells within the red marrow cavities of certain bones.

ANSWER:

- ☒ True
- ☐ False

Chapter 5 True/False Question 2

Description: [[Bloom's Taxonomy: Knowledge]] (a) Articular cartilage covers the diaphysis of long bones.

Part A

Articular cartilage covers the diaphysis of long bones.

ANSWER:

- ☐ True
☒ False

Chapter 5 True/False Question 5

Description: [[Bloom's Taxonomy: Knowledge]] (a) A closed, or simple, fracture is one that penetrates through the skin's surface.

Part A

A closed, or simple, fracture is one that penetrates through the skin's surface.

ANSWER:

- ☐ True
☒ False

Interactive Activity: Abnormal Spinal Curvatures

Description: [[Bloom's Taxonomy: Knowledge]] This sorting activity explains how the abnormal spinal curvatures (scoliosis, lordosis, and kyphosis) differ from one another.

Part A - Abnormal Spinal Curvatures

The vertebral column has primary curvatures of the thoracic and sacral regions and second curvatures of the cervical and lumbar regions. These curvatures give the vertebral column an S-shape. Exaggerations or changes of the normal curves of the column result in abnormal curvatures of the spine.

Drag and drop the name and the description of spinal curvatures to the picture of a patient with that abnormal condition.

ANSWER:



Chapter 5 Reading Quiz Question 7

Description: [[Bloom's Taxonomy: Understanding]] (a) What type of vertebrae have openings in their transverse processes that guide the vertebral arteries up toward the brain?

Part A

What type of vertebrae have openings in their transverse processes that guide the vertebral arteries up toward the brain?

ANSWER:

- ☐ sacral
- ☒ cervical
- ☐ thoracic
- ☐ lumbar

Chapter 5 Chapter Test Question 2

Description: [[Bloom's Taxonomy: Remembering]] (a) Which of these bones is part of the axial skeleton?

Part A

Which of these bones is part of the axial skeleton?

ANSWER:

- ☐ clavicle
- ☐ coxal bone
- ☐ scapula
- ☒ sternum

Chapter 5 Chapter Test Question 9

Description: [[Bloom's Taxonomy: Understanding]] (a) Which spinal curvature develops as an infant begins to hold up his or her head?

Part A

Which spinal curvature develops as an infant begins to hold up his or her head?

ANSWER:

- ☐ lumbar
- ☐ thoracic
- ☒ cervical
- ☐ sacral

Chapter 5 Chapter Test Question 10

Description: [[Bloom's Taxonomy: Analyzing]] (a) What causes the pain associated with a herniated disc?

Part A

What causes the pain associated with a herniated disc?

ANSWER:

- ☐ abnormal spinal curvature pinching the spinal cord
- ☐ vertebral bodies scraping against each other
- ☐ bone spurs pressing against nerves
- ☒ pressure on spinal nerves by the protruding disc

Chapter 5 Chapter Test Question 15

Description: [[Bloom's Taxonomy: Remembering]] (a) What type of joint is found between the atlas and the dens of the axis?

Part A

What type of joint is found between the atlas and the dens of the axis?

ANSWER:

- ☐ plane
- ☐ condylar
- ☐ hinge
- ☒ pivot

The atlas and the dens of the axis form a pivot joint that permits side-to-side movement of the head.

Chapter 5 Homeostatic Imbalance Question 5

Description: [[Bloom's Taxonomy: "Application"]] (a) Miguel has an abnormal forward curvature in the lumbar region, resulting in a swaybacked posture. Miguel has _____.

Part A

Miguel has an abnormal forward curvature in the lumbar region, resulting in a swaybacked posture. Miguel has _____.

ANSWER:

- ☐ scoliosis
- ☐ gout
- ☐ kyphosis
- ☒ lordosis

This is the condition that fits Miguel's symptoms.

Chapter 5 Multiple Choice, Part I, Question 22

Description: [[Bloom's Taxonomy: Knowledge]] (a) Using the figure, identify the following: The parietal bone is indicated by _____.

Part A

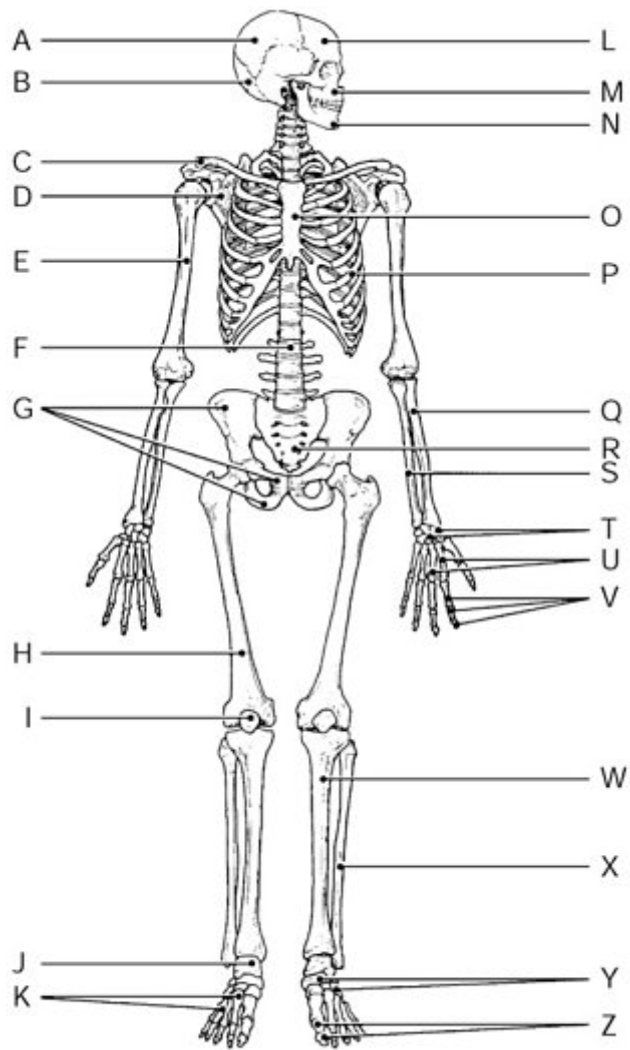


Figure 5.2

Using the figure, identify the following:

The parietal bone is indicated by _____.

ANSWER:

- ☐ Label M
- ☐ Label O
- ☒ Label A
- ☐ Label H
- ☐ Label P

Chapter 5 Multiple Choice, Part I, Question 25

Description: [[Bloom's Taxonomy: Comprehension]] (a) Using the figure, identify the following: The manubrium and xiphoid process are markings on the bone indicated by _____.

Part A

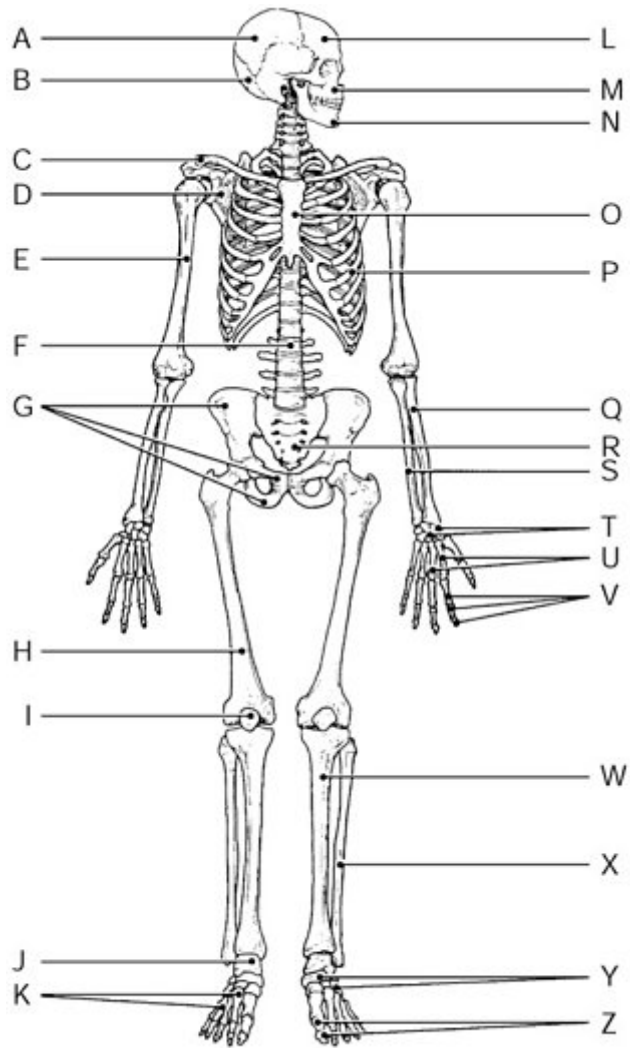


Figure 5.2

Using the figure, identify the following:

The manubrium and xiphoid process are markings on the bone indicated by _____.

ANSWER:

- ☒ Label O
- ☐ Label N
- ☐ Label A
- ☐ Label K
- ☐ Label B

Chapter 5 Multiple Choice, Part I, Question 27

Description: [[Bloom's Taxonomy: Knowledge]] (a) Using the figure, identify the following: The mandible is indicated by _____.

Part A

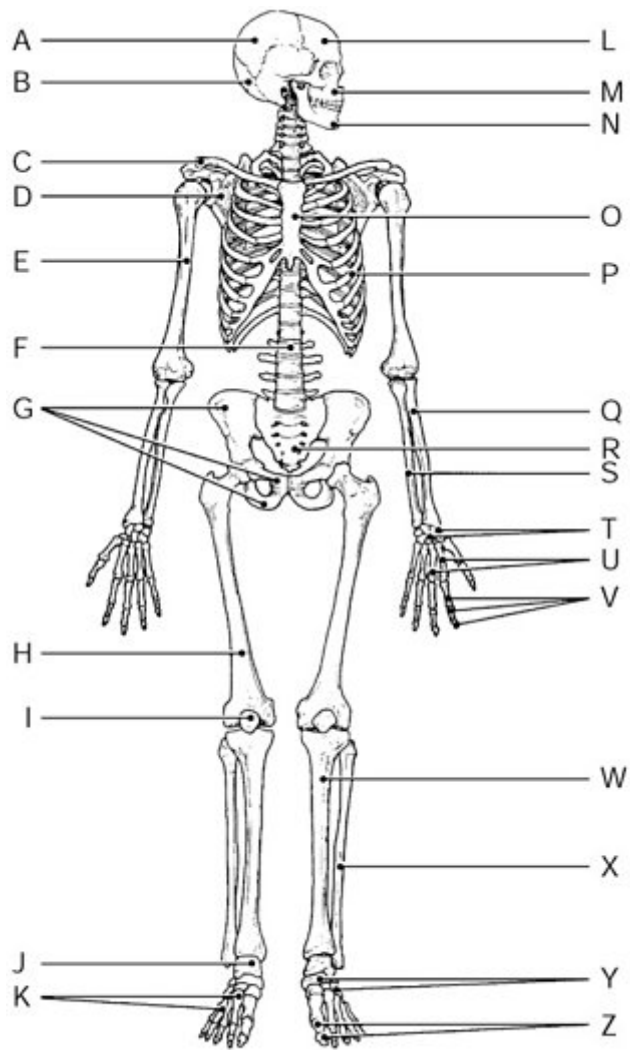


Figure 5.2

Using the figure, identify the following:

The mandible is indicated by _____.

ANSWER:

- ☒ Label N
- ☐ Label W
- ☐ Label M
- ☐ Label C
- ☐ Label B

Chapter 5 Multiple Choice, Part II, Question 12

Description: [[Bloom's Taxonomy: Application]] (a) Which of the following bones is considered part of the axial skeleton?

Part A

Which of the following bones is considered part of the axial skeleton?

ANSWER:

- ☐ radius
- ☒ sternum
- ☐ metatarsals
- ☐ scapula
- ☐ femur

Chapter 5 Multiple Choice, Part II, Question 27

Description: [[Bloom's Taxonomy: Knowledge]] (a) The fibrous connections between the bones of a fetal skull are _____.

Part A

The fibrous connections between the bones of a fetal skull are _____.

ANSWER:

- ☐ alveolar margins
- ☐ palates
- ☒ fontanelles
- ☐ sinuses
- ☐ crista galli

Chapter 5 Multiple Choice, Part II, Question 29

Description: [[Bloom's Taxonomy: Application]] (a) The hyoid bone is unique because it _____.

Part A

The hyoid bone is unique because it _____.

ANSWER:

- ☐ belongs to both the axial and appendicular skeletons
- ☒ is the only bone of the body that does not directly articulate with any other bone
- ☐ has no specific function
- ☐ is an irregular bone
- ☐ largely consists of cartilage

Chapter 5 Multiple Choice, Part II, Question 31

Description: [[Bloom's Taxonomy: Knowledge]] (a) How many true ribs do humans have?

Part A

How many true ribs do humans have?

ANSWER:

- ☒ seven
- ☐ three
- ☐ fifteen
- ☐ five
- ☐ twelve

Chapter 5 Multiple Choice, Part II, Question 37

Description: [[Bloom's Taxonomy: Knowledge]] (a) The tailbone is the _____.

Part A

The tailbone is the _____.

ANSWER:

- ☐ sacrum
- ☒ coccyx
- ☐ ischium
- ☐ pubis
- ☐ patella

Chapter 5 True/False Question 6

Description: [[Bloom's Taxonomy: Comprehension]] (a) The last two pairs of ribs are called true ribs because they have no anterior attachments.

Part A

The last two pairs of ribs are called *true ribs* because they have no anterior attachments.

ANSWER:

- ☐ True
☒ False

Chapter 5 True/False Question 7

Description: [[Bloom's Taxonomy: Knowledge]] (a) Teeth are anchored in the maxillary bones and the mandible.

Part A

Teeth are anchored in the maxillary bones and the mandible.

ANSWER:

- ☒ True
☐ False

Chapter 5 True/False Question 9

Description: [[Bloom's Taxonomy: Knowledge]] (a) The intervertebral discs that cushion the spine and absorb shock are composed of fibrocartilage.

Part A

The intervertebral discs that cushion the spine and absorb shock are composed of fibrocartilage.

ANSWER:

- ☒ True
☐ False

Chapter 5 True/False Question 11

Description: [[Bloom's Taxonomy: Knowledge]] (a) There are seven cervical, twelve thoracic, and five lumbar vertebrae.

Part A

There are seven cervical, twelve thoracic, and five lumbar vertebrae.

ANSWER:

- ☒ True
- ☐ False

Chapter 5 True/False Question 12

Description: [[Bloom's Taxonomy: Comprehension]] (a) A newborn baby has an S-shaped spinal curvature known as a primary curvature.

Part A

A newborn baby has an S-shaped spinal curvature known as a primary curvature.

ANSWER:

- ☐ True
- ☒ False

Chapter 5 Reading Quiz Question 8

Description: [[Bloom's Taxonomy: Remembering]] (a) Which bones form the palm of the hand?

Part A

Which bones form the palm of the hand?

ANSWER:

- ☐ carpal bones
- ☐ metatarsal bones
- ☐ phalanges
- ☒ metacarpal bones

Chapter 5 Multiple Choice, Part I, Question 18

Description: [[Bloom's Taxonomy: Knowledge]] (a) The shin bone is called the _____.

Part A

The shin bone is called the _____.

ANSWER:

- ☐ fibula
- ☐ femur
- ☐ radius
- ☒ tibia

Chapter 5 Multiple Choice, Part I, Question 23

Description: [[Bloom's Taxonomy: Knowledge]] (a) Using the figure, identify the following: The fibula is indicated by _____.

Part A

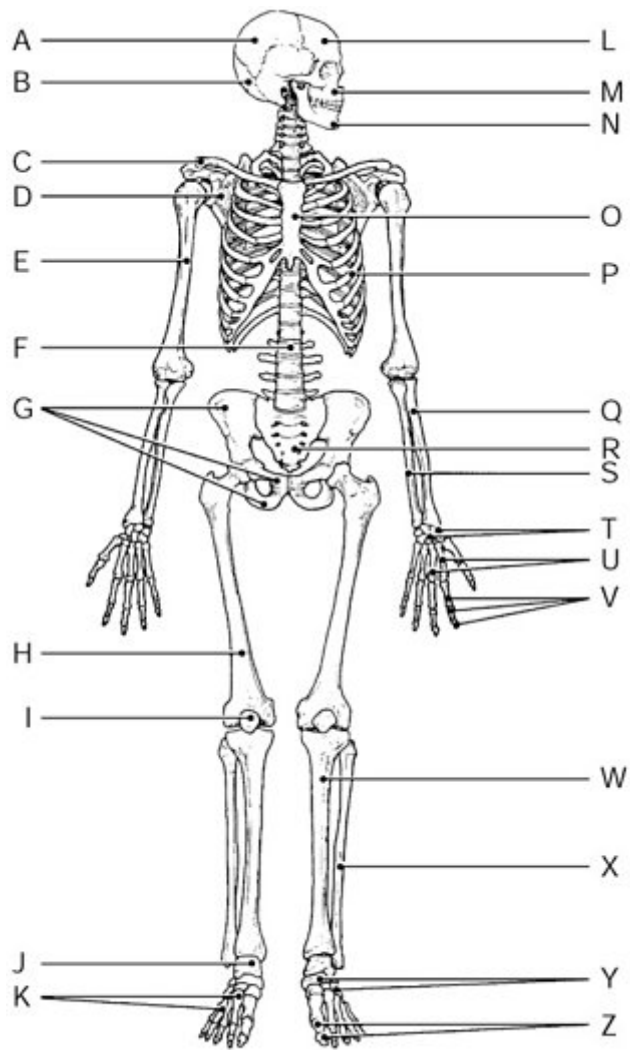


Figure 5.2

Using the figure, identify the following:

The fibula is indicated by _____.

ANSWER:

- ☐ Label Q
- ☒ Label X
- ☐ Label R
- ☐ Label T
- ☐ Label W

Chapter 5 Multiple Choice, Part I, Question 24

Description: [[Bloom's Taxonomy: Knowledge]] (a) Using the figure, identify the following: The patella is indicated by _____.

Part A

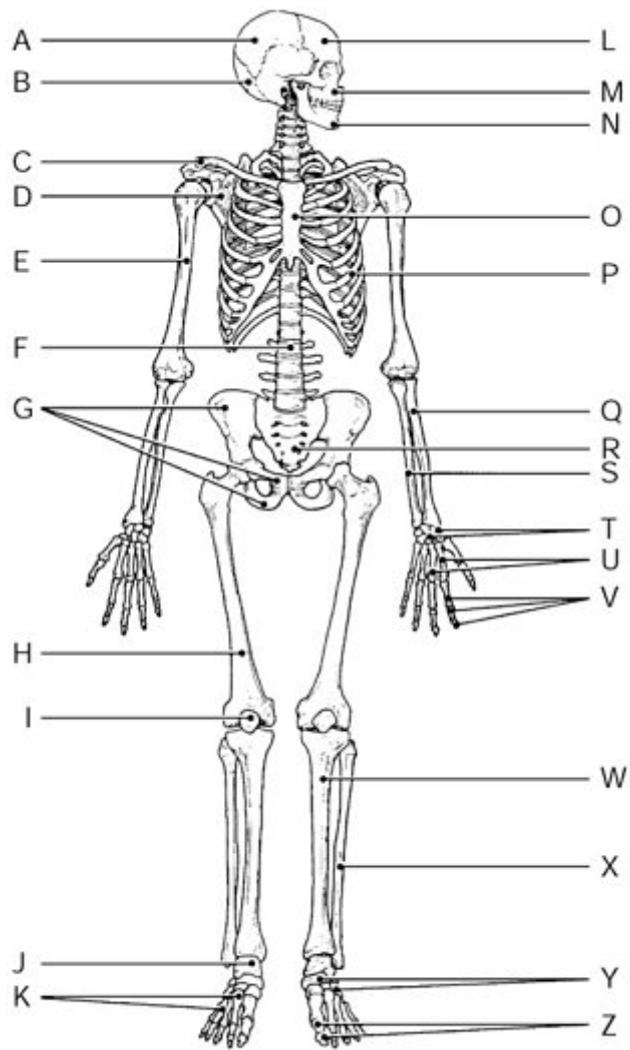


Figure 5.2

Using the figure, identify the following:

The patella is indicated by _____.

ANSWER:

- ☐ Label E
- ☐ Label G
- ☒ Label I
- ☐ Label U
- ☐ Label A

Chapter 5 Multiple Choice, Part I, Question 26

Description: [[Bloom's Taxonomy: Knowledge]] (a) Using the figure, identify the following: The radius bone is indicated by _____.

Part A

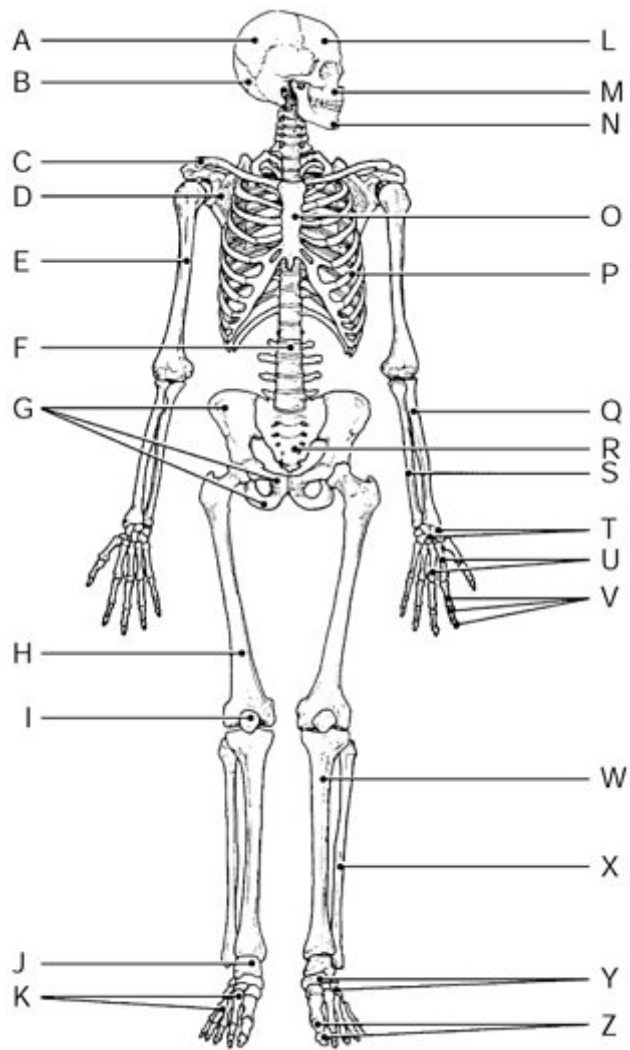


Figure 5.2

Using the figure, identify the following:

The radius bone is indicated by _____.

ANSWER:

- ☐ Label T
- ☐ Label R
- ☐ Label F
- ☐ Label S
- ☒ Label Q

Chapter 5 Multiple Choice, Part I, Question 28

Description: [[Bloom's Taxonomy: Knowledge]] (a) Using the figure, identify the following: The carpals are indicated by _____.

Part A

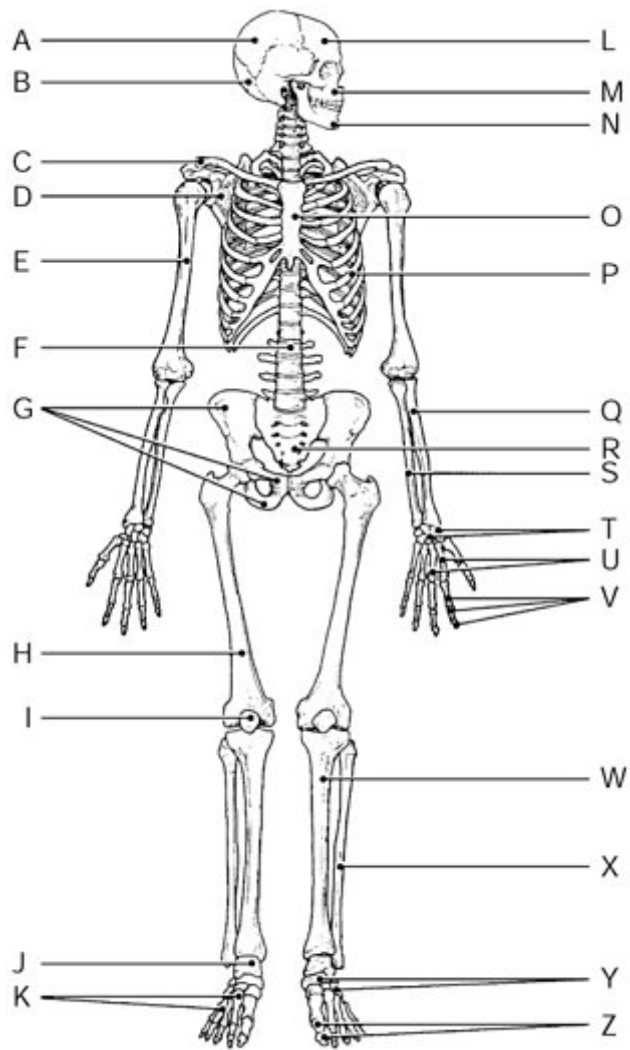


Figure 5.2

Using the figure, identify the following:

The carpals are indicated by _____.

ANSWER:

- ☐ Label N
- ☐ Label X
- ☐ Label J
- ☐ Label I
- ☒ Label T

Chapter 5 Multiple Choice, Part I, Question 29

Description: [[Bloom's Taxonomy: Comprehension]] (a) Using the figure, identify the following: The greater tubercle and trochlea are bone markings situated on the bone marked by _____.

Part A

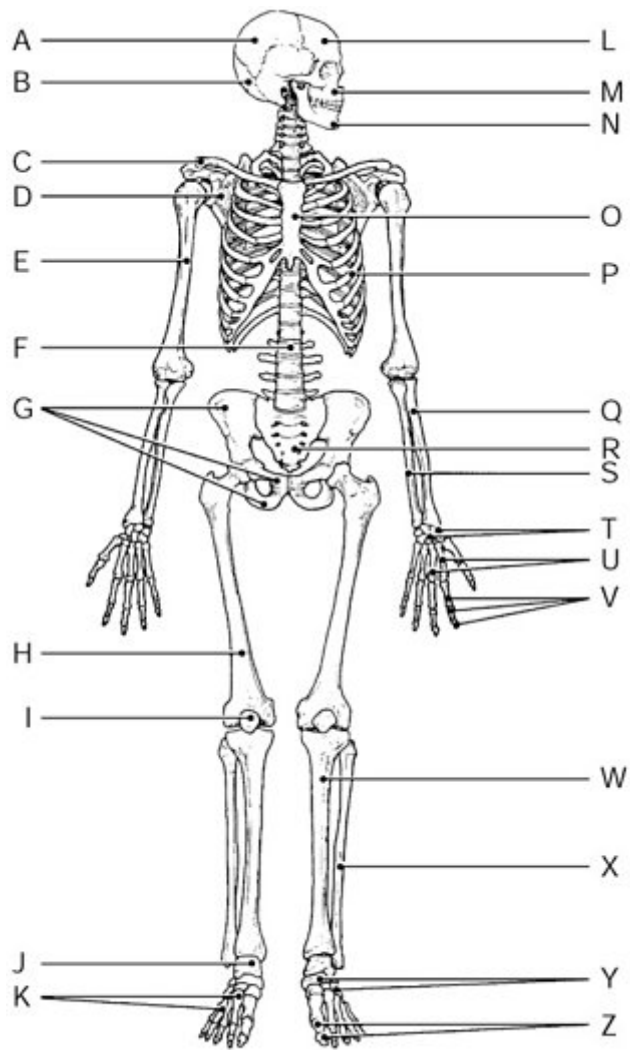


Figure 5.2

Using the figure, identify the following:

The greater tubercle and trochlea are bone markings situated on the bone marked by _____.

ANSWER:

- ☐ Label O
- ☐ Label I
- ☒ Label E
- ☐ Label Y
- ☐ Label A

Chapter 5 Multiple Choice, Part I, Question 30

Description: [[Bloom's Taxonomy: Comprehension]] (a) Using the figure, identify the following: The ilium, pubis, and ischium fuse to form the bone marked by _____.

Part A

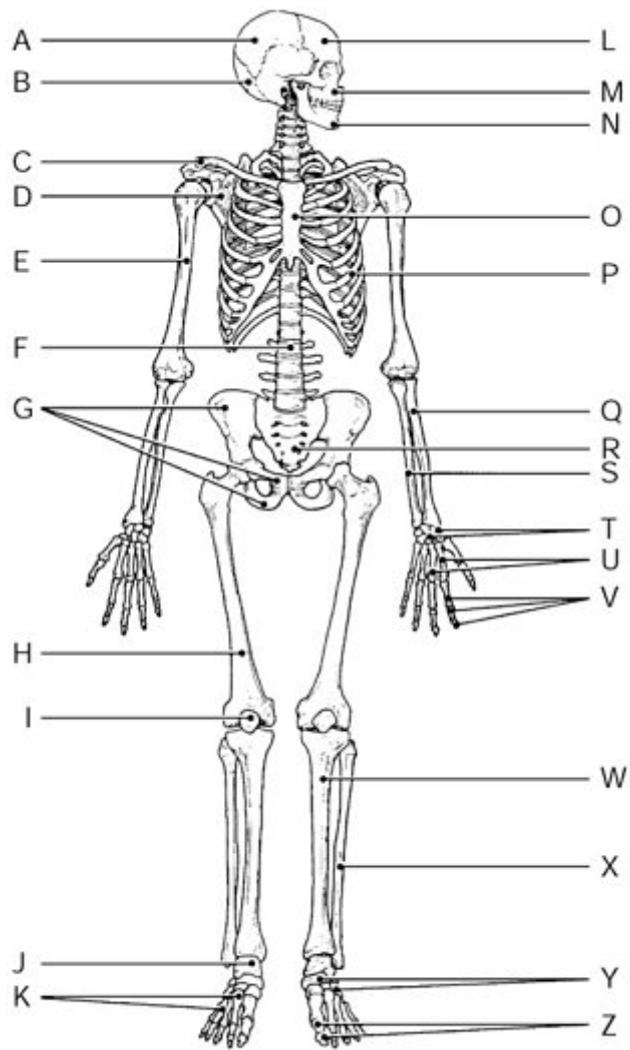


Figure 5.2

Using the figure, identify the following:

The ilium, pubis, and ischium fuse to form the bone marked by _____.

ANSWER:

- ☐ Label F
- ☒ Label G
- ☐ Label T
- ☐ Label H
- ☐ Label I

Chapter 5 Multiple Choice, Part II, Question 28

Description: [[Bloom's Taxonomy: Comprehension]] (a) Which of these bones is associated with the hand?

Part A

Which of these bones is associated with the hand?

ANSWER:

- ☒ metacarpals
- ☐ metatarsals
- ☐ calcaneus
- ☐ tarsals
- ☐ talus

Chapter 5 Multiple Choice, Part II, Question 36

Description: [[Bloom's Taxonomy: Comprehension]] (a) Which two bones constitute the forearm?

Part A

Which two bones constitute the forearm?

ANSWER:

- ☐ femur and fibula
- ☐ humerus and scapula
- ☐ radius and humerus
- ☐ fibula and tibia
- ☒ ulna and radius

Chapter 5 Multiple Choice, Part II, Question 42

Description: [[Bloom's Taxonomy: Knowledge]] (a) The wrist bones are actually _____.

Part A

The wrist bones are actually _____.

ANSWER:

- ☐ metacarpals
- ☒ carpals
- ☐ metatarsals
- ☐ tarsals
- ☐ phalanges

Chapter 5 Multiple Choice, Part II, Question 43

Description: [[Bloom's Taxonomy: Comprehension]] (a) Which of these bones articulates with the acetabulum of the coxal bone?

Part A

Which of these bones articulates with the acetabulum of the coxal bone?

ANSWER:

- ☐ fibula
- ☐ sacrum
- ☒ femur
- ☐ patella
- ☐ tibia

Chapter 5 Multiple Choice, Part II, Question 44

Description: [[Bloom's Taxonomy: Application]] (a) Four of the five answers listed below are parts of the same anatomical area. Select the exception.

Part A

Four of the five answers listed below are parts of the same anatomical area. Select the exception.

ANSWER:

- ☐ radius
- ☐ humerus
- ☒ fibula
- ☐ clavicle
- ☐ scapula

Chapter 5 True/False Question 10

Description: [[Bloom's Taxonomy: Comprehension]] (a) In anatomical position, the lateral lower leg bone is the fibula.

Part A

In anatomical position, the lateral lower leg bone is the fibula.

ANSWER:

- ☒ True
☐ False

Chapter 5 Homeostatic Imbalance Question 6

Description: [[Bloom's Taxonomy: "Knowledge"]] (a) Julie fell off her horse and dislocated her right shoulder. The primary treatment to resolve this injury is _____.

Part A

Julie fell off her horse and dislocated her right shoulder. The primary treatment to resolve this injury is _____.

ANSWER:

- ☒ reduction
☐ remodeling
☐ pain-relieving drugs
☐ bed rest

Reduction is the process of returning the bone to the proper position and should only be done by a trained medical professional.

Chapter 5 Matching Question 11-15

Description: [[Bloom's Taxonomy: Knowledge]] (a) Match the following.

Part A

Match the following.

Drag the terms on the left to the appropriate blanks on the right.

ANSWER:

Reset

Help

1. **Plane joint** Wrist joint

2. **Ball-and-socket joint** Shoulder joint

3. **Hinge joint** Ankle joint

4. **Condylar joint** Knuckle joints

5. **Pivot joint** Joint between atlas and axis

Chapter 5 Multiple Choice, Part I, Question 20

Description: [[Bloom's Taxonomy: Knowledge]] (a) Two or more bones meet at a location called a(n) _____.

Part A

Two or more bones meet at a location called a(n) _____.

ANSWER:

- ☒ articulation (joint)
- ☐ fracture
- ☐ marrow cavity
- ☐ hematoma

Chapter 5 Multiple Choice, Part I, Question 21

Description: [[Bloom's Taxonomy: Knowledge]] (a) Immovable joints are functionally classified as _____.

Part A

Immovable joints are functionally classified as _____.

ANSWER:

- ☒ synarthroses
- ☐ diarthroses
- ☐ amphiarthroses
- ☐ symphyses

Chapter 5 Multiple Choice, Part II, Question 39

Description: [[Bloom's Taxonomy: Comprehension]] (a) The type of joint shown in the figure is _____.

Part A

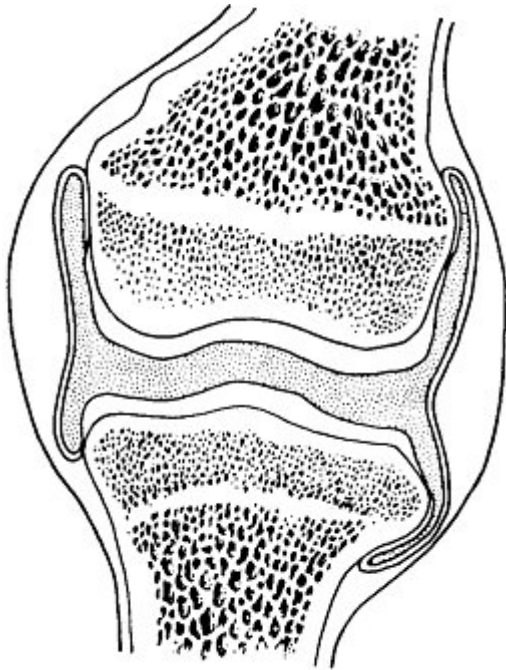


Figure 5.4

The type of joint shown in the figure is _____.

ANSWER:

- ☐ a fibrous joint
- ☐ a cartilaginous joint
- ☐ an amphiarthrotic joint
- ☒ a synovial joint
- ☐ a suture

Chapter 5 Multiple Choice, Part II, Question 45

Description: [[Bloom's Taxonomy: Comprehension]] (a) The elbow is classified as a(n) _____.

Part A

The elbow is classified as a(n) _____.

ANSWER:

- ☐ condylar joint
- ☒ hinge joint
- ☐ pivot joint
- ☐ plane joint
- ☐ saddle joint

Copyright © 2016 Pearson. All rights reserved.

[Legal Notice](#) | [Privacy Policy](#) | [Permissions](#) | [Support](#)